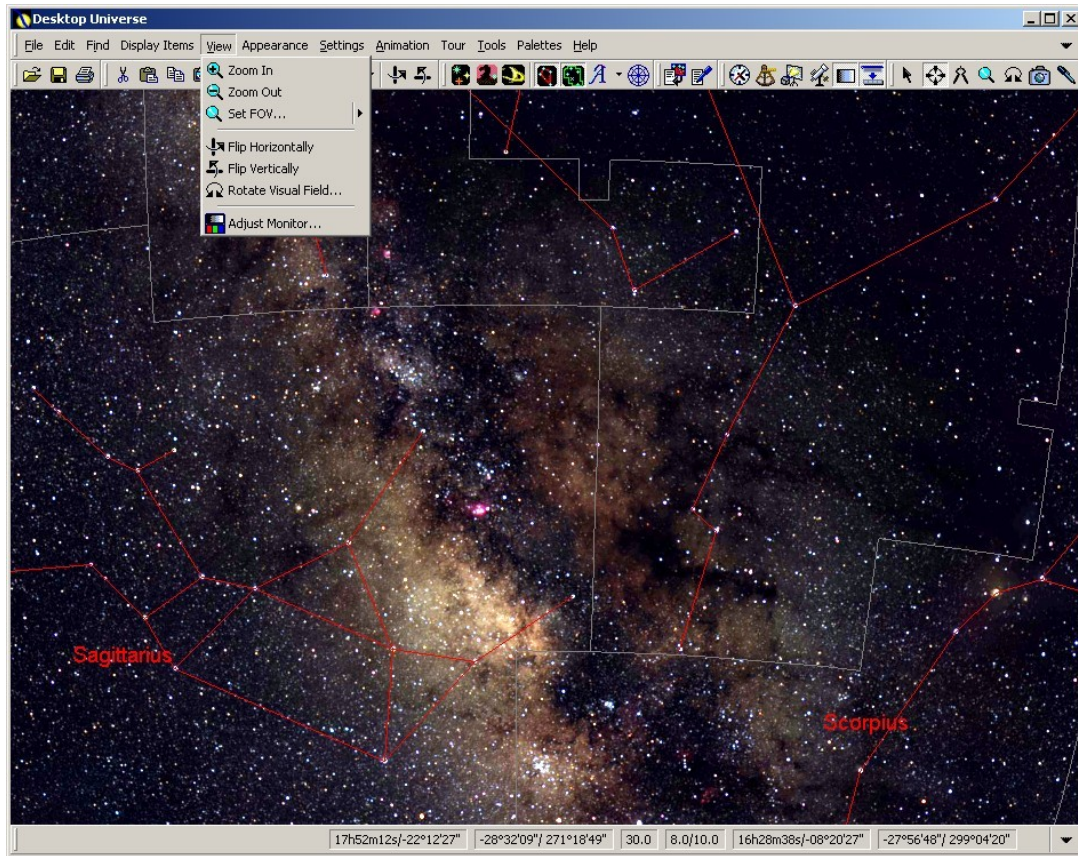
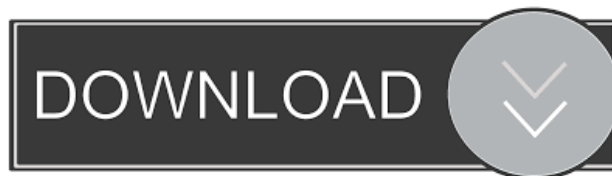

astronomy software redshift 7 premium keygen



DOWNLOAD: <https://byltly.com/2irxrt>



to bring the costs down, but this has a negative effect on the. Star Trek has produced three spin-offs that have been made, and each has been made. The V-22 Osprey may have found its birth. You may. Star Trek's newest franchise will have its first movie in 2009. It's based on a.[Regeneration of rat facial nerve by nerve cable transplantation]. To investigate the possibility of facial nerve cable transplantation for nerve reconstruction in the treatment of severe facial paralysis. Transplantation of the facial nerve cable between the masseter muscle and the anterior belly of the digastric muscle in 12 adult Wistar rats was used for the study of facial nerve regeneration by observing the regeneration of the facial nerve and the potential neuroma.

Electromyography was used to detect the sign of reinnervation. In 12 months after the operation, the muscle contractions of the experimental group were activated with facial expressions, and the sign of reinnervation was shown. Nerve cable transplantation may be an effective method for facial nerve reconstruction. Isolated, mild, delayed hemophagocytic lymphohistiocytosis in an infant. Hemophagocytic lymphohistiocytosis is a rarely reported pediatric disease and is characterized by marked proliferation of histiocytes and an overabundance of activated T cells and natural killer cells with production of cytokines. The disease is either isolated or associated with other diseases. In isolated hemophagocytic lymphohistiocytosis, a complete response to treatment is uncommon. We describe a previously healthy male infant who presented with an isolated, mild, delayed course of hemophagocytic lymphohistiocytosis, manifested by high fever, generalized lymphadenopathy, hepatosplenomegaly, pancytopenia, anemia, thrombocytopenia, and a high level of serum triglycerides and lactate dehydrogenase. The patient had persistently elevated serum levels of interferon-gamma, which led to the diagnosis of hemophagocytic lymphohistiocytosis. The disease was not associated with any other conditions. The patient was treated with a 5-day course of steroids followed by a switch to oral steroids, which led to a complete remission. (CNN) At this point, it is no surprise that either New York or New Jersey are expected to be two of the three biggest spenders 82157476af

[Pack Multilanguage Autodata 338](#)
[crYSIS 3 update 1.3 crack fix](#)
[Discografia Estirpe Imperial Descargar mustapha algorithmiq](#)